

2026 UTHSC Surgical Oncology Symposium

Cases Presentations for Panel Discussions

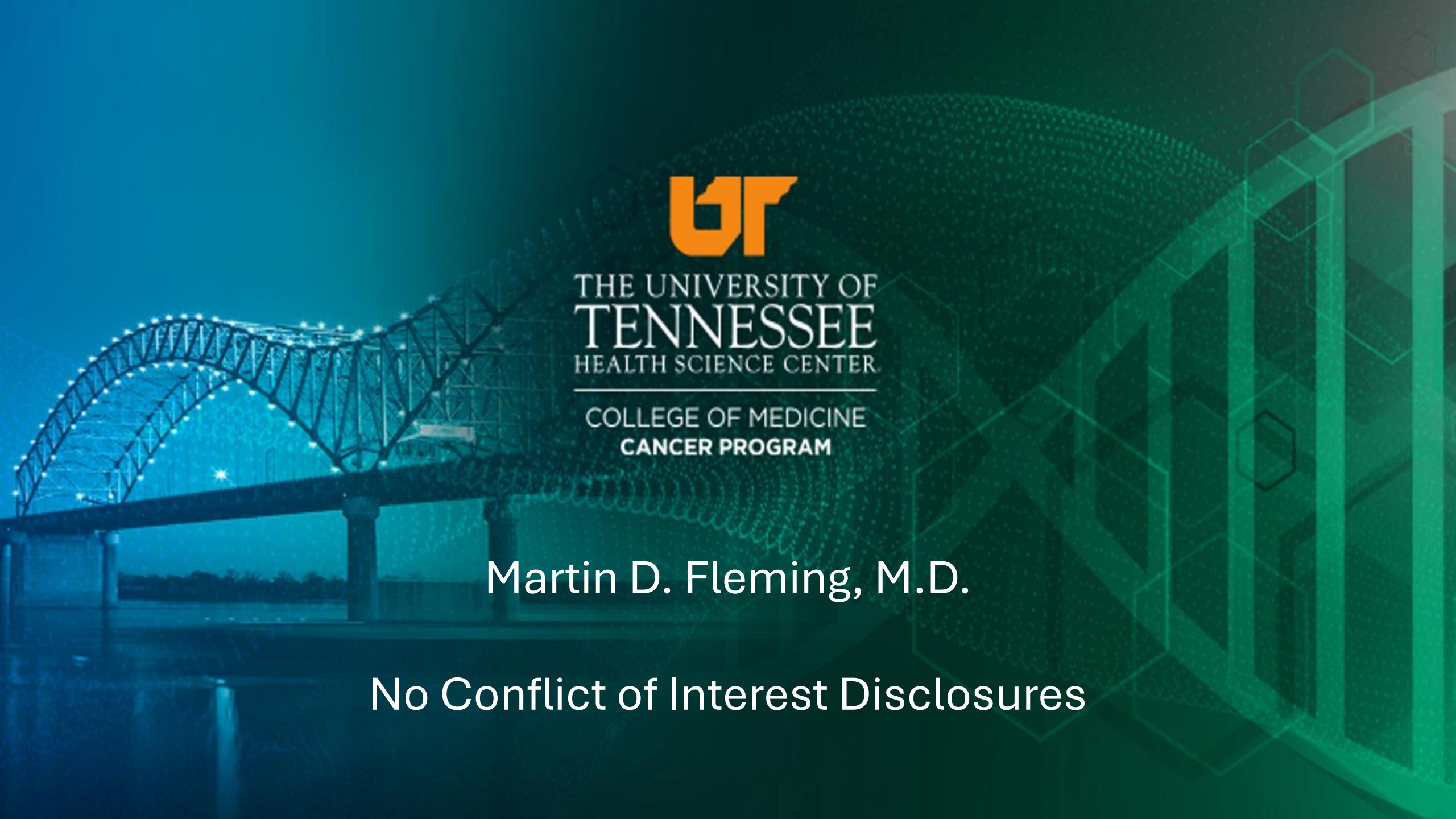

Martin D. Fleming, M.D.

No Conflict of Interest Disclosures

Case # 1

- The patient is a 67-year-old female with no significant past medical history who was referred to surgical oncology clinic for a left forearm mass.
- She stated that she first noticed the mass in 2022 when she could no longer button the sleeve of her blouses on her left arm.
- She stated that she went to a surgeon this year because for the past year she had been dealing with her mother who was sick and recently passed away. After her mother passed away, she felt like she had time to take care of the swelling in her arm.
- She is right-hand dominant.
- She has never had a problem like this before. She stated that the mass seem to appear out of nowhere but has also not significantly grown in size over the past 2 years.
- She stated that she does not have any pain for the mass but occasionally experiences some numbness and tingling in her fingertips. No significant loss of sensation throughout her hand or forearm, however. She does experience some weakness of grip strength but is still able to perform all of her usual activities of daily living.
- CT of scan of her left arm was obtained at a hospital in Houston Mississippi, and she brought the CT disc to the surgeon she saw in Tupelo. She forgot to bring the disc to surgical oncology clinic today. She stated that she will bring it at her next appointment.
- She was agreeable to having an MRI of her left arm obtained if she could get something for medication. She is also agreeable to have an ultrasound guided biopsy of her forearm after the MRI. Discussed with her that she we will follow-up in surgical oncology clinic to discuss the results of the biopsy and imaging after they are performed and discuss next steps. Review of Systems

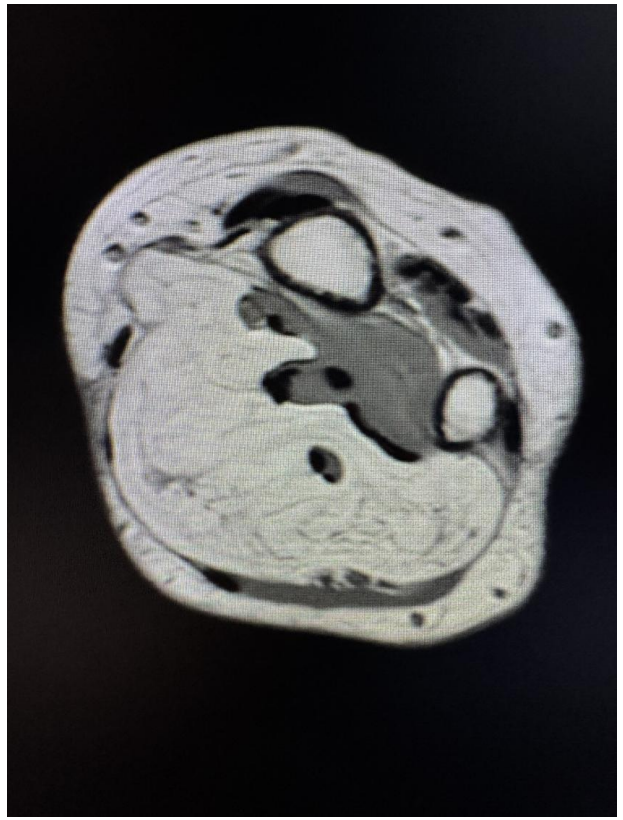



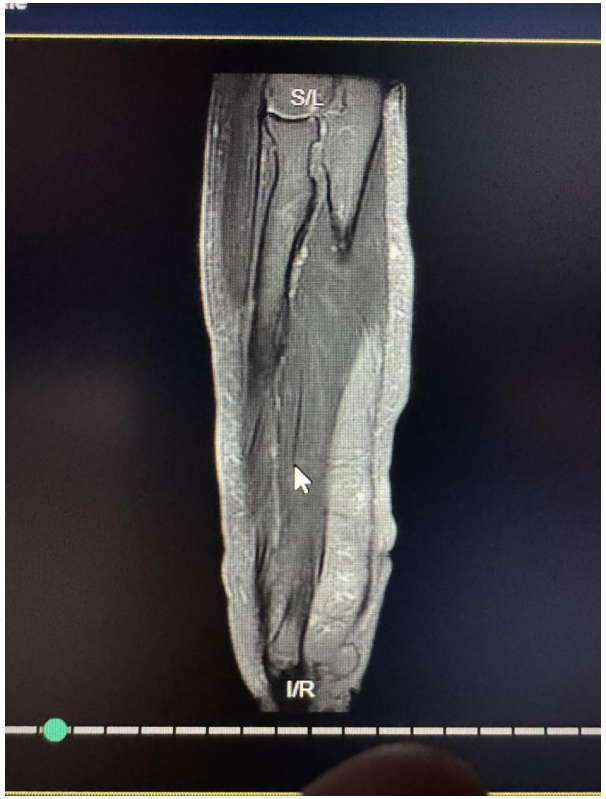



MRI was review in office today as well as Chest CT which shows NED.

Ultrasound Guided biopsy:

Pathology: Mature Lipomatous mass with positive MDM2 amplification by FISH, consistent with well differentiated liposarcoma.

- Next Steps in care?
  - Neoadjuvant XRT?
  - Neoadjuvant systemic therapy?
    - Chemotherapy vs. immunotherapy?

We discussed her surgery as a Limb Salvage procedure with resection of the liposarcoma. She was told that it is most likely low grade liposarcoma but if we do find that it is high grade, she will need possible chemotherapy and or radiation. Pt is scheduled for surgery.

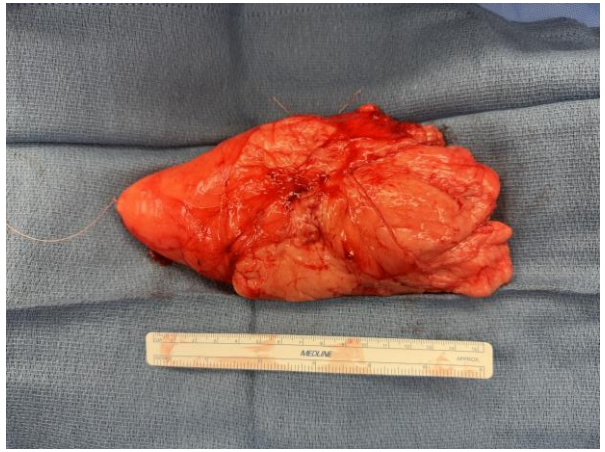





Surgical Pathology:

+ for Atypical Lipomatous Tumor
Tumor Shows no evidence of high-grade dedifferentiation
Tumor abuts inked margins, but correlation and gross assessment of the specimen is recommended for determining the adequacy of resection.

- Next Steps in care?
  - Adjuvant XRT?
  - Adjuvant systemic therapy?

    Chemotherapy vs. immunotherapy?

- Patient seen for follow up at q 3 intervals with plans chest CT and left upper extremity MRI every 6 months.
- Pt with significant anxiety about Ct scans or MRI requiring medicine for imaging.
- Pt seen in follow up on 10/23/2026:
- Patient is a 69yo woman here today for a 3 month follow up, history of liposarcoma of the left forearm, resected 2/25/25. She reports no issues, some pulling when lifting heavy equipment, but this has been stable since surgery. She notes that she had an MRI on the left forearm the same day as her chest CT which was done at North MS medical center in Tupelo on 12/17/24. These were negative for any evidence of recurrence or metastatic disease.
- She cancelled her previous routine imaging. In the past, when she had her previous MRI at North Mississippi Medical Center, she was able to do it on her stomach, but when she went to North Mississippi Imaging, she was made to lay on her back. She says that she will not be able to undergo a CT or MRI scan if she has to lay on her back. She is not interested in taking anxiolytics to be able to tolerate the imaging.
- Physical exam demonstrates a normally function left upper extremity and no mass effect.
- We will continue to follow up at regular intervals with imaging whenever patient can tolerate it.

- Next Steps in care?
  - Alternative imaging modalities
  - Alternative follow schedule or screening efforts

Case # 2

- The Patient is a 42 y/o male who presented in October of 2025 for a newly biopsied dedifferentiated liposarcoma of the right retroperitoneum.
- His story starts when he saw his primary care physician and stated that he had right lower and abdominal pain.
- He also complains of normal 4 bowel movements a day that increased to 10 in the last month with blood and mucus.
- They did blood work of CBC and CMP which was unremarkable.
- His past medical history is only remarkable for viral myocarditis in 2016.

He had a CT Chest which was negative for staging by Dr Portnoy. He had a CT CAP done 8/11/25 at Methodist which stated 1) large right retroperitoneal mass measuring 19 x14.5 x 23.2 cm, Retroperitoneal sarcoma favored. Alternatively GI stromal tumor from duodenum could be considered. This is amenable to percutaneous biopsy.

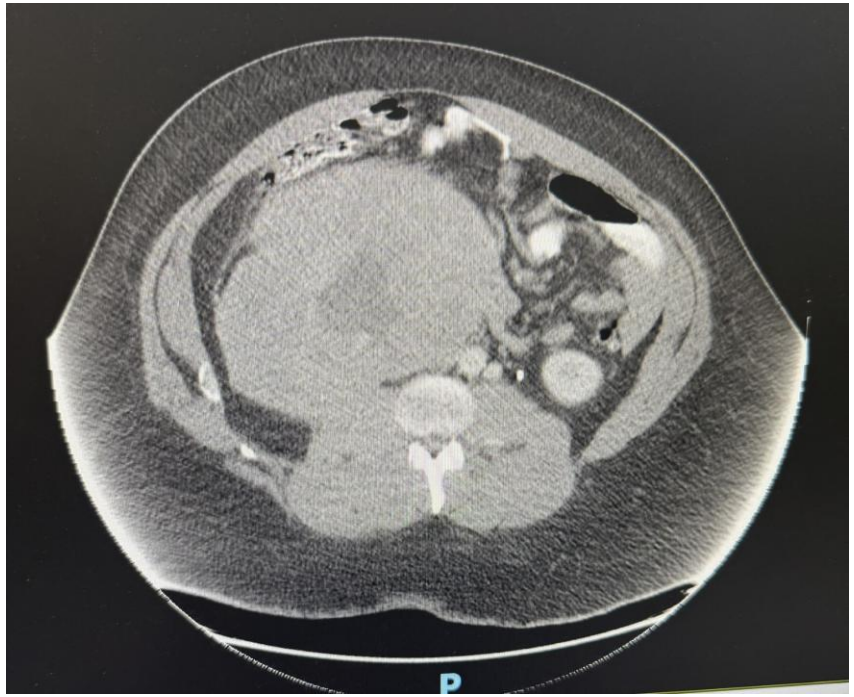





- He then underwent a CT Guided biopsy on 9/10/25 and pathology states spindle cell sarcoma consistent with dedifferentiated liposarcoma, MDM2 amplification detected by FISH.

- He had a CT Chest for staging which was negative for metastatic disease

- Next Steps in care?
    - Neoadjuvant XRT?
    - Neoadjuvant systemic therapy?
        - Chemotherapy vs. immunotherapy?

- He was told that he will not need chemotherapy and would not need radiation pre-surgery.
- It will be determined after surgery if he will need radiation due to margin status. His MRI of the abdomen done 10/17/25 shows: 16 cm x 24 cm x 25.5 cm right retroperitoneal mass displacing the viscera and vasculature of the right hemi-abdomen.
- He is was referred for primary surgical resection.

On 12/9/25 pt underwent abdominal exploration and complete removal of dedifferentiated liposarcoma.

Path: High Grade Dedifferentiated liposarcoma, MDM2 amplification +, margins positive “focally at an inked exophytic nodule in the capsule”

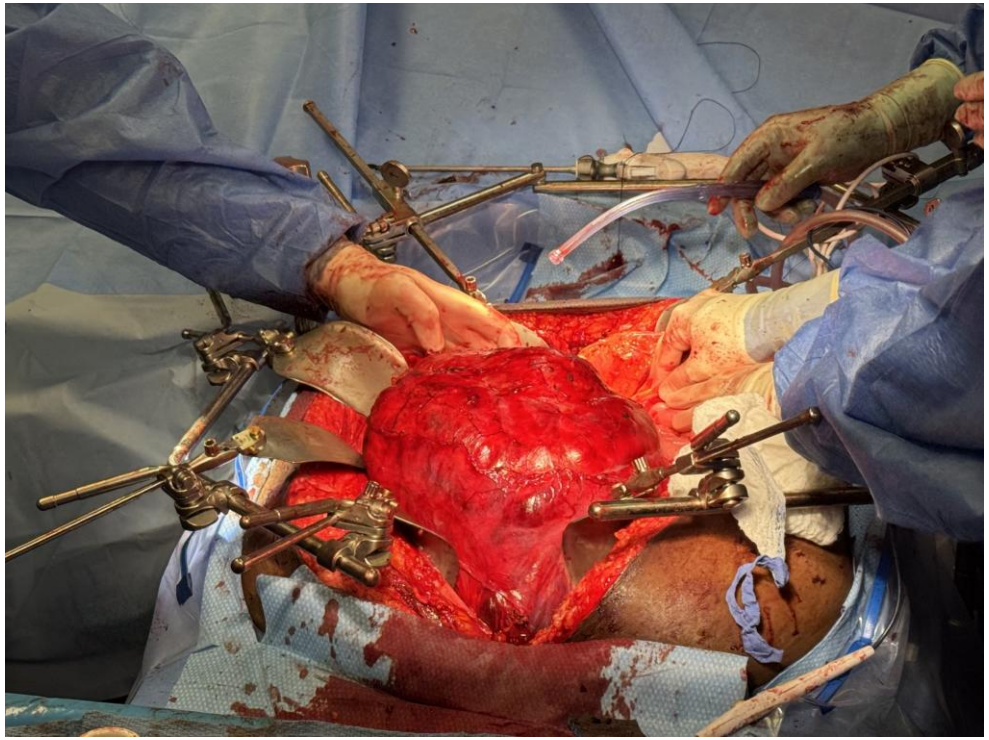



- Next Steps in care?
  - Adjuvant XRT?
  - Adjuvant systemic therapy?
    - Chemotherapy vs. immunotherapy?

- Emergency Room Visit on 10/3/2026 to “Re establish Care”

- “On interview patient reports that he has been having abdominal pain for the past 3 months. He also has been experiencing early satiety and bloating, and energy has been going on for the past few months. He has been using oxycodone as needed which caused some constipation that he is treating with over-the-counter Dulcolax. No fever or chills, no night sweats, no weight loss. No nausea or vomiting. No lumps noted abundant but positive for abdominal distention.”

- CT scan 10/3/26

- Underwent IR bx of abdominal mass on 10/5/26



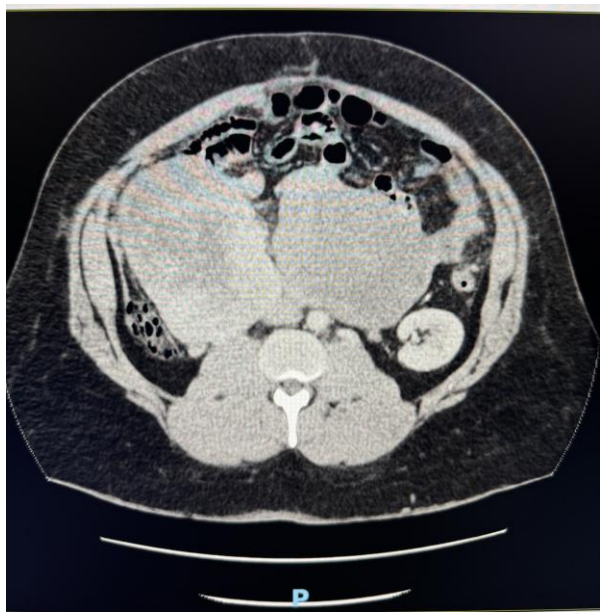

CT scan 10/3/26 showed large heterogeneous enhancing multilobulated retroperitoneal mass measuring 27.3 x 25 x 12.3 cm with moderate mass effect the proximal inferior vena cava. No metastatic disease on imaging. Underwent IR bx of abdominal mass on 10/5/26



Pt underwent CT Guided Biopsy on 10/5/2026

Abdominal mass, biopsy:

- **High-grade sarcoma, consistent with dedifferentiated liposarcoma**
- **See comment**

ADDENDUM COMMENT
Per clinician's request, immunohistochemical stains for mismatch repair (MMR) are performed and shows retained nuclear expression for all markers (MLH1, MSH2, MSH6 and PMS2). There is no evidence of deficient mismatch repair (low probability of MSI-H).

ORIGINAL COMMENT
Immunohistochemical stains show the cells of interest to be positive for CD34 and MDM2 while negative for S100, desmin, STAT6 and pancytokeratin.

Patient's history of a dedifferentiated liposarcoma is noted.

Overall findings are supportive of the diagnosis

- Next Steps in care?
  - Adjuvant XRT?
  - Adjuvant systemic therapy?
    - Chemotherapy vs. immunotherapy?

Case # 3

74-year-old, otherwise female presented to ED because of abdominal pain, weight loss of 20 lbs. over 4 months, early satiety. CT demonstrated a large left upper quadrant mass.

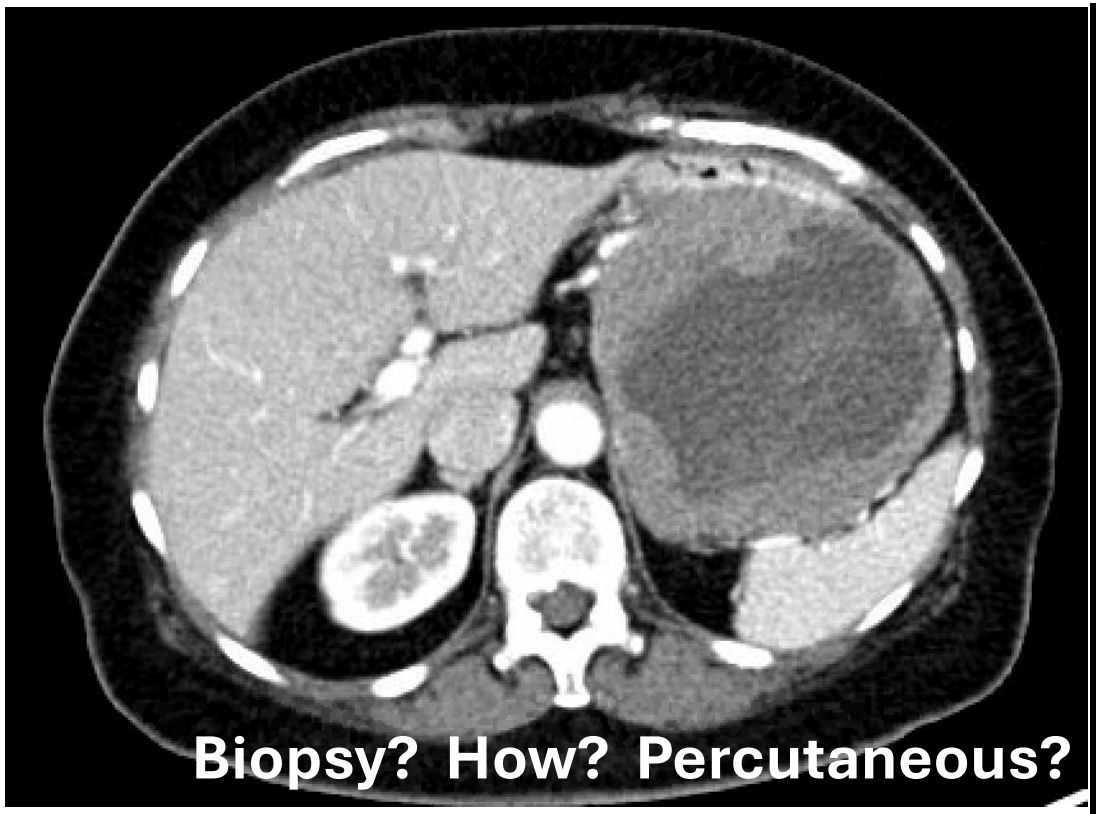



Patient underwent percutaneous biopsy, which demonstrated gastrointestinal stromal tumor (GIST), spindle cell, mitotic index 100 mitoses/5mm^2.

PET CT demonstrates 12.6 x 11.2 x 8.9 cm mass with peripheral FGD enhancement and internal necrosis. Mass appears to arise from the body of the stomach. No evidence of distant metastatic disease.

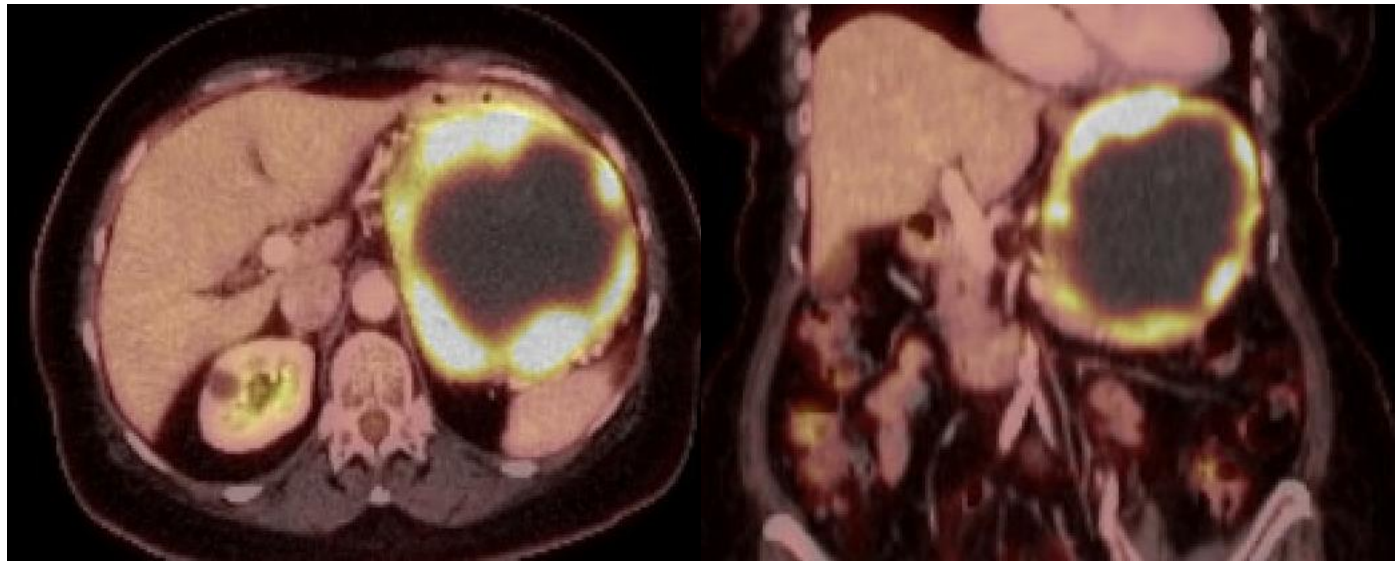

Neoadjuvant Therapy vs Upfront Resection?

Decision was made to undergo upfront resection. At laparotomy, large, vascular mass arising from the posterior wall of the body of the stomach with obliteration of gastrosplenic ligament and adherence to the tail of the pancreas. Had partial gastrectomy with en bloc distal pancreatectomy/splenectomy to achieve resection.

Gastrointestinal stromal tumor, spindle cell type, high grade G2 (15.0 cm).

- Tumor arising from gastric muscularis propria with well-defined dense capsule, adhered to pancreas and splenic hilum.
- No infiltrating pattern of tumor seen (grossly and microscopically).
- Tumor reveal approximately 73 % central necrosis, gross.
- Tumor shows approximately 10 mitoses per high power field, microscopically.
- No lymph nodes submitted or found.
- Risk of progressive disease: High (86%).
- Margins are free of tumor.

Pathologic Stage Classification: pT4 pNX pMX R0

Surgical Pathology Slides

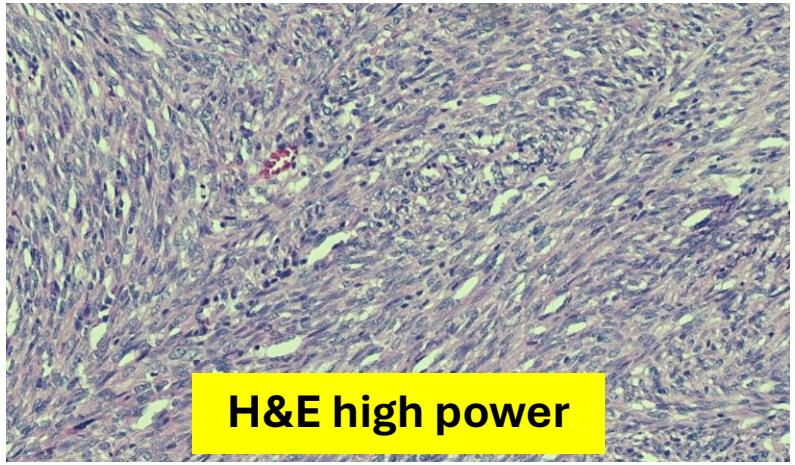

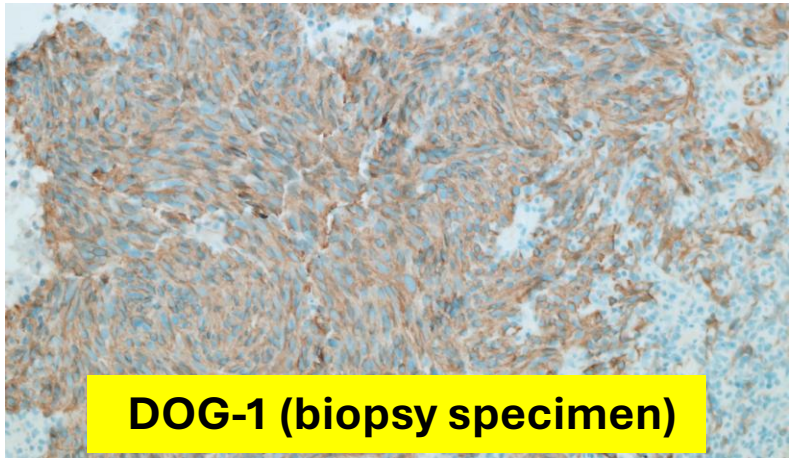

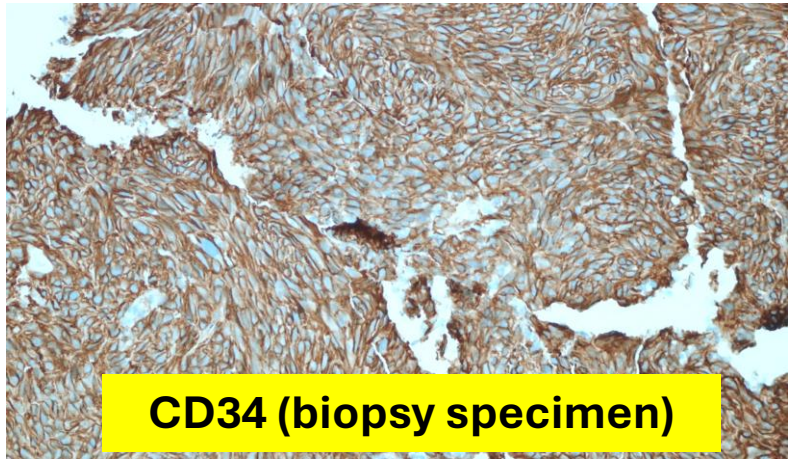

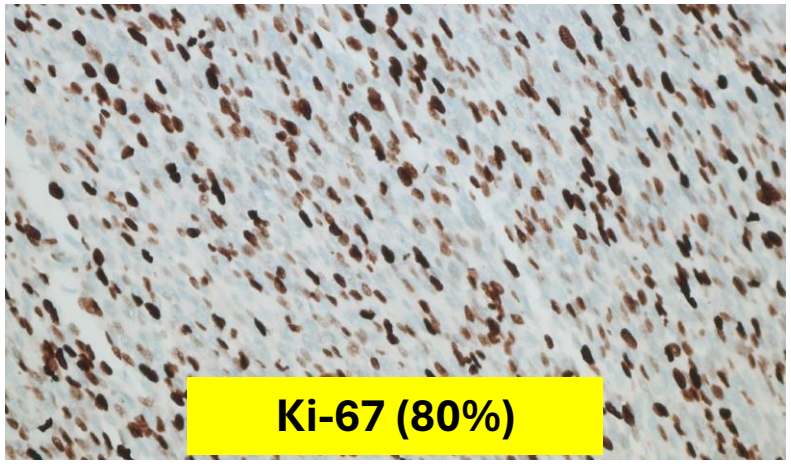

What next?

Exon mutational testing?

Type and recommended length of treatment?

Prognosis?

Case # 4

- Follow Up appointment on 3/9/2026:
- He has been traveling a lot lately for his job and states that overall, he is tired but doesn't think it has to do with his surgery but rather that he has been busy. He did see and establish care with PCP 2/18/26 and states that she told him his kidney function was improving.
- He has not yet established care with a nephrologist.
- He did also go and see medical oncology and states that he was happy with his visit.
- He had a CT scan CAP done 2/16/26 which stated:
  Impression:
  1) interval resection of retroperitoneal liposarcoma.
  2)Ill defined density along the right common iliac chain which is indeterminate for residual tumor, adenopathy, or post operative changes. Comparison with prior outside imaging is recommended. Further evaluation with PET/CT would be of value.

- Because of the results of the scan above, a PET/CT was ordered which was done an showed no evidence of recurrent sarcoma.
- He states that overall, he feels well and has only minor pain occasionally when he bends down to tie his shoe- which could be residual pain post operatively from the ribs.
- His incision is also sensitive with keloidal areas on the upper incision. He was scheduled for an ECHO tomorrow but was cancelled due to insurance coverage.

- Pt patient is a 61yo male new patient in clinic for an anterior chest wall mass.
- He presents with a large 10 cm plus protruding mass from his upper central chest.
- His history involves him noticing this mass first September 2023 around the size of "half his fist". It has steadily increased in size and started to grow rapidly around January 2024.
- Says he works mowing lawns for living.
- Due to insurance issues, he was not able to schedule an appointment to establish care until March of 2025. Since then, he says the mass has gotten bigger but does not have any associated pain, erythema, and he denies any issues with breathing, swallowing, excessive drooling, voice changes, lightheadedness, dizziness, chest pain, shortness of breath, nausea, vomiting, heart palpitations, skin changes or rashes. No night sweats, no other lymphadenopathy, no hemoptysis or hematemesis. Denies any fevers, chills, history of increased weight, decreased weight, trouble sleeping, or temperature regulation issues. Says he works mowing lawns for living.

He had an ultrasound guided neck biopsy 5/24/24 which showed final diagnosis: Neck Mass Biopsy- Chondrosarcoma Grade 2 with necrosis (report from Mayo Clinic).

He had a CT neck soft tissue 3/24/25 for re-staging




P



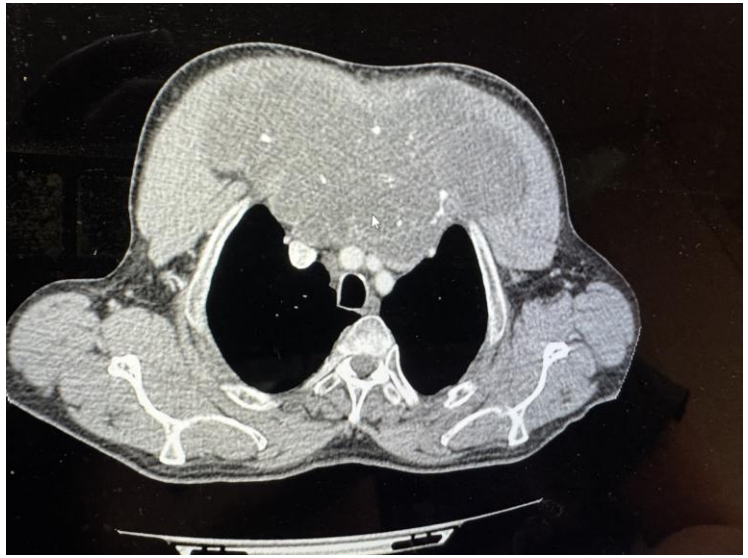

- Next Steps in care?
  - Neoadjuvant XRT?
  - Neoadjuvant systemic therapy?
    - Chemotherapy vs. immunotherapy?


ADULT LONG
CRITIKON



UTHSC Cancer Program



UTHSC
Cancer Program









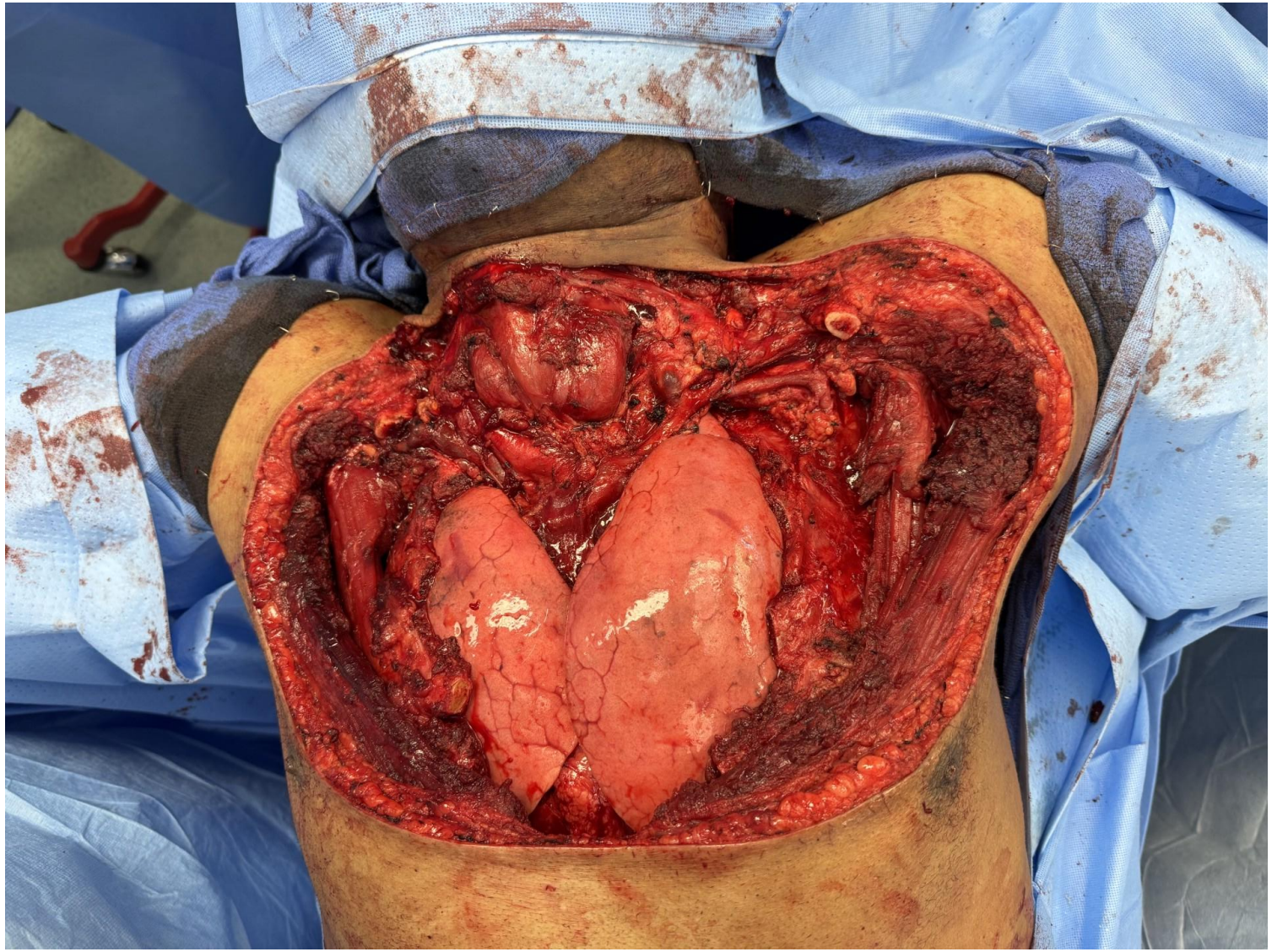



CT Scan 12/5/2025

Multiple new multilobulated masses within the bilateral chest. Largest in left supraclavicular area measuring 6.6 x 9.5x 12cm

Multiple pleural based masses. Largest being 9 x 4,4x 6.0cm

Anterior Mediastinal mass measuring 7.5 x 7.6 x 4.9cm abutting the pericardium with multiple additional masses along the pericardial lining.



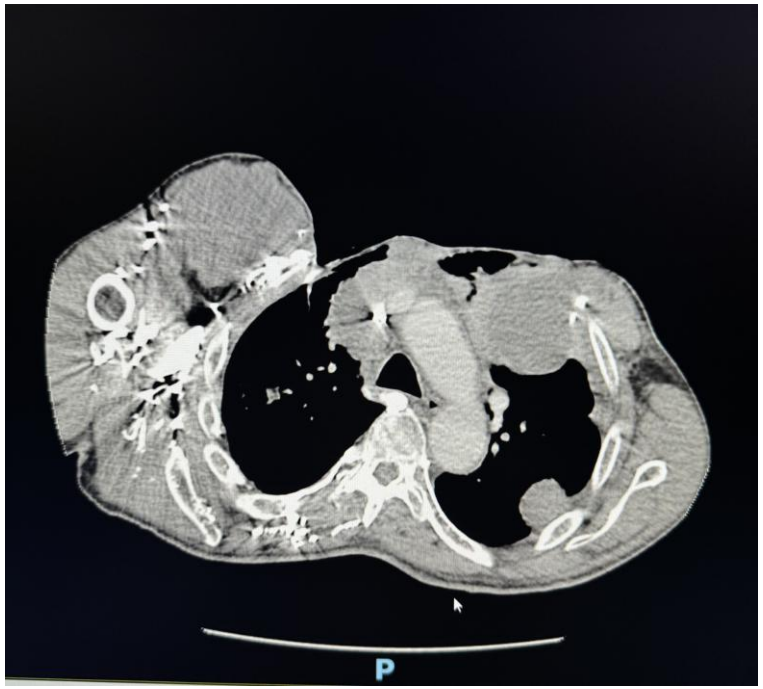

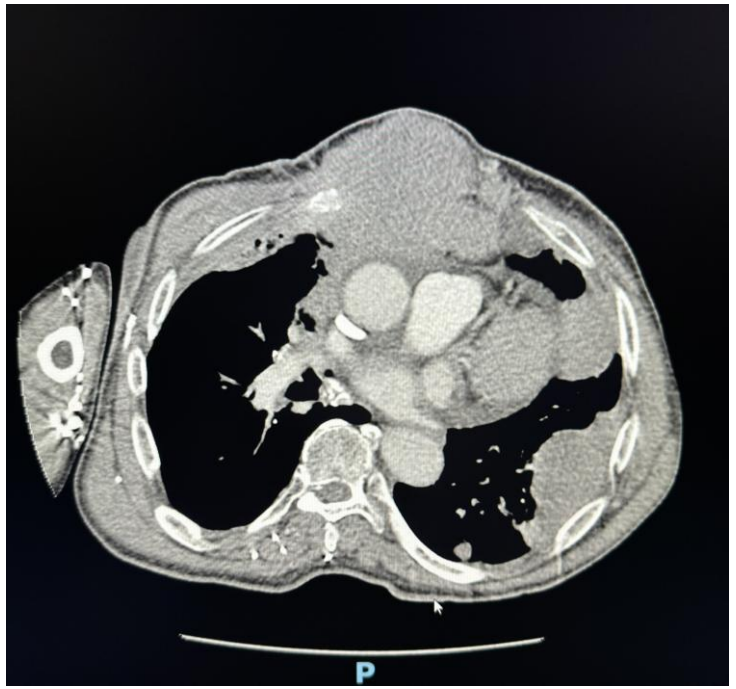

- Next Steps in care?
  - Adjuvant XRT?
  - Adjuvant systemic therapy?
    - Chemotherapy vs. immunotherapy?

Case # 5

- The patient is a 64 year-old female who presented on 1/24/24 with a history of 6x4x3cm undifferentiated grade 3 spindle cell carcinoma (University of Michigan) on the left medial knee that was excised on 12/13/2023 at an outside hospital.
- The final pathology reveals microscopic positive margins.
- She states that the mass had been present for ~1 year and began experiencing soreness of her left knee.
- Prior to the excision, she had an US of her left lower leg that showed a heterogeneously hypoechoic mass.
- Ct of the Chest + for scattered indeterminant pulmonary nodules all less than 6mm

Post Op MRI of the left leg + for a post op fluid collection (hematoma vs seroma)





- Radical re-resection preformed on 2/29/2024, with the deep margin down to the periosteum of the medial femoral condyle.
- On 3/15 patient presented postop from radical resection of left knee sarcoma on 2/29/2024. She was doing well. She had no complaints other than expected postop discomfort that was improving with each day.
- Pathology + for a small nodule of residual high-grade sarcoma with all surgical margins now negative but with the closest margin (deep) < 1 mm
- Pt presented at multidisciplinary sarcoma conference and, due to the very close deep margin and the high-grade histology, external beam radiation recommended.
- Pt underwent full six week course of external radiation to the operative field.

- She was seen again on 10/31/2025. She had a normal physical exam without and evidence of local recurrence of the sarcoma but she had failed to have her scheduled imaging.
- She had her last scans 1/24/25 when she was here for her last apt. She had both a CT chest and MRI of the left lower leg which were both showing stable changes since last scans and no evidence of disease.
- She knows that she has to have scans the next time she is here for her follow up apt, and requests to have them done in February instead of January 2026.
- Pt represented on 9/4/26 follow up. She was unable to make her original scheduled appointment in February due to conflicts with family in January, the ice storm in February, her and her husband being sick, and her taking care of her aunt. She canceled her February appointment. Another appointment was not made and she never returned to clinic.
- Come this past May she reported some increased left knee swelling and pain. It has felt warm and more difficult to move.
- In August, she decided to go to a clinic near home where an US was done on her leg to assess for abscess vs DVT. This was negative, except for some fluid collection. The NP gave her a course of antibiotics that she reports that it helped with swelling but otherwise her leg is the same.
- When the swelling continued she made an appointment to return for evaluation.
- She had a repeat chest CT and MRI of her left knee this morning.

She had a repeat chest CT that showed no evidence of metastatic disease.

MRI of her left knee demonstrated a fluid collection with inflammatory changes.



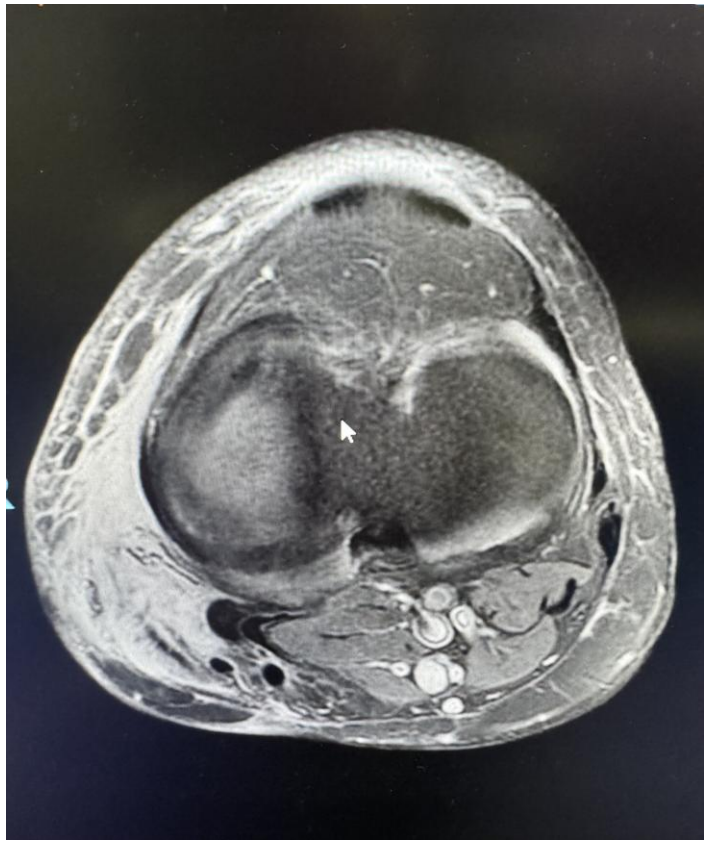

- She had an IR performed an US guided aspiration of the fluid collection in the L medial knee and sent the fluid for cytology and culture which were both negative.
- We rescheduled her for a core needle biopsy of the surrounding soft tissue. That was performed on
- The results of her soft tissue bx done on 10/12/26-
- "A) left medial knee- spindle cell carcinoma, consistent with recurrence of known undifferentiated spindle cell sarcoma. Sarcoma is patchy positive for CD34 and is negative for CK OSCAR, S100, smooth muscle actin and desmin.“

- Next Steps in care?
  - Additional Adjuvant XRT?
  - Additional Surgery
    - Repeat limb salvage effort
      Above Knee Amputation
  - Adjuvant systemic therapy?
    - Chemotherapy vs. immunotherapy

Questions?

THE UNIVERSITY OF TENNESSEE HEALTH SCIENCE CENTER

COLLEGE OF MEDICINE
CANCER PROGRAM



2026 UTHSC Surgical Oncology Symposium

Cases Presentations for Panel Discussions